
Practice Guidelines for Performance of the Routine Mid-Trimester Fetal Ultrasound Scan

ISUOG Prenatal Ultrasound Screening Task Force

Clinical Standards Committee

The International Society of Ultrasound in Obstetrics and Gynecology (ISUOG) is a scientific organization that encourages sound clinical practices, teaching, and research for diagnostic imaging in women's health care. The ISUOG Clinical Standards Committee (CSC) has a remit to develop Practice Guidelines and Consensus Statements as educational recommendations that provide health care practitioners with a consensus-based approach for diagnostic imaging. They are intended to reflect what is considered by ISUOG to be currently the best practices at the time they were issued. Although ISUOG has made every effort to ensure that guidelines are accurate when issued, neither the Society nor any of its employees or members accepts any liability for the consequences of any inaccurate or misleading data, opinion, or statements issued by the CSC. They are not intended to establish a legal standard of care because interpretation of the evidence that underpins the guidelines may be influenced by individual circumstances and available resources. Approved guidelines can be freely distributed with the permission of ISUOG (info@isuog.org).

This article has been accepted for publication in *Ultrasound in Obstetrics & Gynecology* and is currently being edited and typeset. Readers should note that this article has been fully refereed, but has not been through the technical editing, copy-editing and proof correction process. Wiley-Blackwell and the International Society of Ultrasound in Obstetrics and Gynecology cannot be held responsible for errors or consequences arising from the use of information contained in this article; nor do the views and opinions expressed necessarily reflect those of Wiley-Blackwell or the International Society of Ultrasound in Obstetrics and Gynecology

A. INTRODUCTION:

Ultrasonography is widely used for the prenatal evaluation of growth and anatomy as well as for the management of multiple gestations. This procedure provides diagnostic findings that often facilitate the management of problems arising in later pregnancy. As an example, abnormal fetal growth is a leading cause of perinatal morbidity and mortality among both industrialized and developing countries. In 2005, the World Health Organization (WHO) concluded that impaired fetal growth had many causes related to genetic factors, maternal characteristics, such as nutrition, lifestyle including smoking, age and disease; complications of pregnancy; and the physical, social and economic environment (1, 2). A mid-trimester fetal ultrasound scan serves as an important baseline against which later scans may be compared for the evaluation of growth and health. Ultrasonography can also be used to detect congenital anomalies (3-6). The Eurofetus study examined the accuracy of routine mid-trimester ultrasonographic examination in unselected populations (7). This multicenter project involved 61 obstetrical ultrasound units from 14 European countries. Over one-half (56%) of 4,615 malformations were detected and 55% of major anomalies were identified before 24 weeks of gestation.

Although many countries have developed local guidelines for the practice of fetal ultrasonography, there are still many areas of the world where they have not been implemented. Most countries offer at least one mid-trimester scan as part of standard prenatal care although obstetrical practice varies widely around the world. This can be related to the availability of qualified practitioners and equipment, local medical practice, and legal considerations; in some countries, insurance-related cost reimbursements strongly influence how routine mid-trimester scans are implemented. Nonetheless, a WHO Study Group stated, "Worldwide, it is likely that much of the ultrasonography currently performed is carried out by individuals with in fact little or no formal training." (8). The intent of this document is to provide further guidance for health care practitioners in the performance of mid-trimester fetal ultrasound scan

B. GENERAL CONSIDERATIONS:

What is the purpose of a mid-trimester fetal ultrasound scan ?

The main objective of a routine mid-trimester fetal ultrasound scan is to provide accurate diagnostic information for the delivery of optimized antenatal care with the best possible outcomes for mother and fetus. This procedure is used to determine gestational age and fetal measurements for the timely detection of growth abnormalities later in pregnancy. Other goals are to detect congenital malformations and multiple pregnancies.

Prenatal screening examination includes an evaluation of the following:

- Cardiac activity
- Fetal number (and chorionicity if multiple pregnancy)
- Fetal age/size
- Basic fetal anatomy
- Placental appearance and location

Although many malformations can be identified, it is acknowledged that some may be missed even with sonographic equipment in the best of hands or they may develop later in pregnancy. Before starting the examination, a health care practitioner should counsel the woman/couple regarding the potential benefits and limitations of a routine mid-trimester fetal ultrasound scan

Who should have a mid-trimester fetal ultrasound scan?

Many countries routinely offer at least one routine mid-trimester fetal ultrasound scan. As one example, an imaging workshop organized by the Eunice Kennedy Shriver National Institute of Child Health and Human Development in the United States (9) reached a consensus that all pregnant women should be offered an ultrasound scan for the detection of fetal anomalies and pregnancy complications. Serial scans may be helpful for some mothers with risk factors for adverse pregnancy outcome (e.g. hypertension or diabetes) and others may benefit from more detailed scans that are targeted to their specific situation. Repeated or detailed examinations, however, are not considered to be routine scans.

When should the mid-trimester fetal ultrasound scan be performed?

A routine mid-trimester ultrasound scan is often performed between 18 and 22 weeks of gestation. This period represents a compromise between dating the pregnancy (more accurate if established earlier) and the timely detection of major congenital anomalies. Countries where pregnancy termination is restricted should balance detection rates against the time needed for counseling and additional investigation. Some centers perform the anatomic survey using transvaginal scanning at approximately 13-16 weeks gestation. This earlier approach can provide useful information about gestational age as a baseline for growth assessment or determination of chorionicity for twins, but may require special training for the early interpretation of anatomic structures

Who should perform the mid-trimester fetal ultrasound scan ?

Individuals who routinely perform obstetrical scans should have specialized training for the practice of diagnostic ultrasonography in pregnant women. However, the requirements for this activity may vary depending on each country.

In order to achieve optimal results from routine screening examinations it is suggested that scans should be performed by individuals that fulfill the following criteria:

- trained in the use of diagnostic ultrasonography and related safety issues
- regularly perform fetal ultrasound scans
- participate in continuing medical education activities
- have established appropriate referral patterns for suspicious or abnormal findings
- routinely undertake quality assurance and control measures (10)

What ultrasonographic equipment should be used?

For routine screening, equipment should have at least the following capabilities:

- real time, grey scale ultrasound capabilities
- transabdominal ultrasound transducers (3 – 5 MHz range)

- adjustable acoustic power output controls with output display standards.
- freeze frame capabilities
- electronic calipers
- capacity to print/store images
- regular maintenance and servicing are important for optimal equipment performance.

What document should be produced/stored/printed or sent to the referring health care provider?

An examination report should be produced either as an electronic and/or paper document sent to the referring care provider in reasonable time. A sample reporting form is available as Supplemental material on the Journal website. Images of standard views (stored either electronically or as printed copies) should also be produced and stored. Motion videoclips are especially useful for the fetal heart. Local laws should be followed. Many jurisdictions require image storage for a defined period of time.

Is prenatal ultrasonography safe?

Prenatal ultrasonography appears to be safe for clinical practice. To date, there has been no independently confirmed study to suggest otherwise. Fetal exposure times should be minimized using the lowest possible power output needed to obtain diagnostic information using the ALARA principle (As Low As Reasonably Achievable). More details are available from the ISUOG Safety Statement (11).

What if the examination cannot be performed in accordance to these guidelines?

These recommendations represent minimum practice guidelines for the mid-trimester fetal ultrasound scan. Consideration must be given to local circumstances and medical practices. Reasons for deviations from these recommendations should be documented. If the examination cannot be completely performed in accordance to adopted guidelines, the scan should be repeated, at least in part at a later time, or the patient can be referred to another practitioner. This should be done as soon as possible, to minimize unnecessary patient anxiety

and unnecessary delay in the potential diagnosis of congenital anomalies or growth disturbances.

What is the role of a more detailed ultrasonographic examination?

Individuals who perform ultrasonographic scans during pregnancy should have referral mechanisms in place to manage suspected or detected abnormalities. A minimum examination, following the guidelines presented herein, should be performed before referring the patient unless technical factors prevent completion of the initial evaluation.

C. GUIDELINES FOR EXAMINATION:

FETAL BIOMETRY AND WELL BEING:

The following sonographic parameters can be used to estimate gestational age and for fetal size assessment (12-14):

1. Biparietal diameter (BPD)
2. Head circumference (HC)
3. Abdominal circumference (AC) or diameter (AD)
4. Femur diaphysis length (FDL)

Measurements should be performed in a standardized manner on the basis of strict quality criteria (15). An audit of results can help to ensure accuracy of techniques with regard to specific reference tables. An image (s) should be taken to document the measurement (s). Examples of still images appropriate for fetal biometry are demonstrated in **Figure 1**.

If gestational age has not already been established at a “dating scan” or “first trimester scan”, it should be determined at the mid-trimester scan on the basis of fetal head size (BPD and/or HC) or femur diaphysis length (FDL). The chosen reference standards should be indicated in the report (16). Subsequent scans should not be used to recalculate a new estimated date of confinement if age has already been established by a high quality scan during earlier pregnancy. Subsequent measurements, optimally at least 2 weeks from a

preceding scan, are usually reported as deviations from mean values with their expected ranges for a given age. This information can be expressed as Z scores, percentile reference ranges, or on a graph although the degree of deviation from normal at this early stage of pregnancy that would justify action (e.g. a follow-up scan to assess fetal growth or fetal chromosomal analysis) has not been firmly established.

Combination of measurements significantly improves the accuracy compared with the prediction based on HC alone (17). However, the clinical significance of this improvement is marginal because the improved accuracy represents less than one day (18).

A. BIPARIETAL DIAMETER (BPD):

Anatomy:

Cross-sectional view of the fetal head at the level of the thalami.

Ideal angle of insonation is 90° to the midline echoes

Symmetrical appearance of both hemispheres

Continuous midline echo (falx cerebri) broken in middle by the
cavum septi pellucidi and thalamus

No cerebellum visualized

Caliper placement:

Both calipers should be placed according to a specific methodology because more than one technique has been described (e.g. 'leading edge to leading edge' versus 'outer edge to outer edge') at the widest part of the skull using an angle that is perpendicular to the midline falx (**Figure 1**) (19). The technique used to establish the reference chart should be used. The cephalic index is a ratio of the maximum head width to its maximum length. Abnormalities in head shape (e.g. dolichocephaly and brachycephaly) can lead to misleading estimates of fetal age when the BPD is used under these circumstances, in which case the HC is more reliable (20).

B. HEAD CIRCUMFERENCE (HC):

Anatomy:

Same as described for the BPD, ensuring that the circumference placement markers correspond to the technique described on the reference chart.

Caliper placement:

If the ultrasound equipment has ellipse measurement capacity, then the HC can be measured directly by placing the ellipse around the outside of the skull bone echoes (**Figure 1**). Alternatively, the HC can be calculated from the BPD and occipitofrontal diameter (OFD) by using the equation $HC = 1.62 \times (BPD + OFD)$. This technique to calculate HC makes special corrections for skull and skin thickness and requires that the calipers be placed at specific sites: BPD leading edge, OFD middle of the bone echo at forehead and occiput.

C. ABDOMINAL CIRCUMFERENCE (AC):

Anatomy:

Transverse section of the fetal abdomen (as circular as possible)

Umbilical vein at the level of the portal sinus.

Stomach bubble visualized

Kidneys should not be visible.

Caliper placement:

The AC is measured at the outer surface of the skin line either with ellipse calipers or it can be calculated from linear measurements made perpendicularly to each other, usually the anterior-posterior abdominal diameter (APAD) and transverse abdominal diameters (TAD) (**Figure 1**). To measure the APAD the calipers are placed on the outer borders of the body outline from the posterior aspect (skin covering the spine) to the anterior abdominal wall. To measure the TAD the calipers are placed on the outer borders of the body outline, across the

abdomen at the widest point. The AC is calculated using the formula $AC = \pi (APAD + TAD)/2 = 1.57(APAD + TAD)$ or by a direct ellipse measurement.

D. FEMUR DIAPHYSIS LENGTH (FDL)

Anatomy:

The femur diaphysis length is optimally imaged with both ends of the ossified metaphysis clearly visible (21, 22). The longest axis of the ossified diaphysis is measured. The technique used to establish the reference chart should be used with regard to the angle between the femur and the insonating ultrasound beams. An angle of insonation between 45 and 90 degrees is typically used for this purpose.

Caliper placement:

Each caliper is placed at the ends of the ossified diaphysis without including the distal femoral epiphysis if it is visible and avoiding the artifactual triangular spurs that appear to extend the length of the femoral ends (**Figure 1**).

E. ESTIMATED FETAL WEIGHT (EFW)

Mid-trimester sonographic measurements can be used to identify abnormalities of fetal size (23, 24). Some countries also use this information to estimate fetal weight as a baseline parameter for the detection of subsequent growth problems. Many “size discrepancies” are explained by incorrect menstrual age estimates, even in women with “certain dates” (25, 26). If gestational age is determined at an earlier scan, EFW can be compared to dedicated normal, preferably local, reference ranges for this parameter (14, 27, 28). However, the degree of deviation from normal at this early stage of pregnancy that would justify action (e.g. follow-up scan to assess fetal growth or fetal chromosomal analysis) has not been firmly established.

F. AMNIOTIC FLUID ASSESSMENT

Amniotic fluid volume can be estimated subjectively or from using sonographic measurements. Subjective estimation is not inferior to the quantitative measurement techniques (e.g. deepest pocket, amniotic fluid index) when performed by experienced examiners (29, 30). Patients with deviations from normal should have more detailed anatomical evaluation and clinical follow up.

G. FETAL MOVEMENT

Normal fetuses typically have a relaxed position and show regular movements. There are no specific movement patterns at this stage of pregnancy. Temporary absence or reduction of fetal movements during the scan should not be considered as a risk factor (31). Abnormal positioning or unusually restricted or persistently absent fetal movements may suggest abnormal fetal conditions such as arthrogryposis (32). The biophysical profile is not considered as part of a routine mid-trimester scan (33).

H. DOPPLER ULTRASONOGRAPHY:

The application of Doppler techniques is not currently recommended as part of the routine second trimester ultrasound examination. There is insufficient evidence to support universal use of uterine or umbilical artery Doppler evaluation for the screening of low risk pregnancies (34-36).

I. MULTIPLE GESTATION:

The evaluation of multiple pregnancies should include the following additional elements:

- Visualization of the placental cord insertion
- Distinguishing features (gender, unique markers, position in uterus)
- Determination of chorionicity is sometimes feasible in the second trimester if there are clearly two separate placental masses and discordant genders.

Chorionicity is much better evaluated before 14-15 weeks (lambda or “t-sign”).

Abnormalities of umbilical cord insertion into the placenta, such as velamentous cord insertion, are more common in multiple gestations and can be associated with several pregnancy complications such as fetal growth restriction, vasa previa, and abnormal fetal heart rate patterns (37, 38). Unfortunately, many cases of vasa previa may not be recognized during pregnancy (39).

Follow up of multiple pregnancies should be arranged in accordance to local guidelines and clinical practices.

ANATOMIC SURVEY

Recommended minimum requirements for a basic fetal anatomic survey during the mid-trimester of pregnancy are summarized in **Table 1**.

A. HEAD

SKULL:

Four areas of the fetal skull should be routinely evaluated: size, shape, integrity and bone density. All these characteristics can be visualized at the time of the head measurements and when the brain is evaluated for anatomic integrity (**Figure 2**) (40).

Size: Measurements are performed as mentioned in the biometry section.

Shape: The skull normally has an oval shape without focal protrusions or defects and interrupted only by narrow echolucent sutures. Alterations of shape (e.g. lemon, strawberry, cloverleaf, etc) should be documented and investigated (41).

Integrity: No bony defects should be present. Rarely, brain tissue can extrude through defects of the frontal or occipital bones although cephaloceles may occur at other sites as well.

Density: Normal skull density is manifested as a continuous echogenic structure that is interrupted only by cranial sutures in specific anatomical locations. The absence of this whiteness or extreme visibility of the fetal brain should raise suspicion of poor mineralization (e.g. osteogenesis imperfecta, hypophosphatasia) (42). Poor mineralization is also suggested when the skull becomes easily depressed as a result of manual pressure from transducer placement against the maternal abdominal wall.

BRAIN:

Standard scanning planes for the basic examination of the fetal brain have already been described in an ISUOG guideline document (<http://www.isuog.org>) (19). Two axial planes permit visualization of the cerebral structures relevant to the anatomic integrity of the brain. These planes are commonly referred to as the transventricular and transthalamic planes (**Figure 2**). Imaging artifacts may obscure the hemisphere closest to the transducer. A third axial transcerebellar plane can be added to evaluate the posterior fossa. The following brain structures should be evaluated:

- lateral ventricles (including choroid plexi)
- cavum septi pellucidi
- thalami
- cerebellum
- cisterna magna

B. FACE

Suggested views for minimum evaluation of the fetal face include the presence of both orbits (**Figure 3a**), evaluation of the nose/nostrils and presence of the mouth (**Figure 3b**). If

technically feasible, a median facial profile view can be obtained (**Figure 3c**). A coronal view of the upper lip can be used to identify cleft lip anomalies (43).

C. NECK

The neck normally appears as cylindrical with no protuberances, masses or fluid collections (44). Obvious neck masses such as cystic hygromas or teratomas should be documented.

D. THORAX

The shape should be regular with a smooth transition to the abdomen (45). The ribs should have normal curvature without deformities. Both lungs should appear homogenous and without evidence for mediastinal shift or masses. The diaphragmatic interface can often be visualized as a hypoechoic dividing line between the thoracic and abdominal content (e.g. liver and stomach) (46, 47).

E. FETAL HEART

General considerations for cardiac examination:

The 'basic' and 'extended basic' cardiac ultrasonographic examinations are designed to maximize the detection of congenital heart disease during a second-trimester scan (**Figure 4**) (48). A single acoustic focal zone and relatively narrow image field of view can help to maximize frame rates. Images should be magnified until the heart fills at least a third to one half of the display screen.

'Basic cardiac' examination:

The basic cardiac screening examination is interpreted from a four-chamber view of the fetal heart. A normal regular rate ranges from 120 to 160 beats per minute. The heart

should be located in the left chest (same side as the fetal stomach) if the situs is normal. A normal heart is usually no larger than one-third the area of the chest and without pericardial effusion. The heart is normally deviated about 45 ± 20 degrees (2 SD) toward the left side of the fetus (49).

'Extended basic' cardiac examination

An 'extended basic' evaluation which includes the aortic and pulmonary outflow tracts can increase the detection rates for major cardiac malformations above those achievable by the four-chamber view alone. Additional views to the basic examination are more likely to identify conotruncal anomalies such as tetralogy of Fallot, transposition of the great arteries, double outlet right ventricle, and truncus arteriosus. Normal great vessels are approximately equal in size and should cross each other as they exit from their respective ventricular chambers.

Some investigators have described an optional 'three-vessels and trachea view' that may also be useful for evaluating the pulmonary artery, ascending aorta, and right superior vena cava in terms of their relative sizes and anatomic relationships (50). For a more detailed description of fetal cardiac screening, the reader is referred to the ISUOG guidelines for the fetal cardiac examination. This document can be downloaded from the Society's website (www.isuog.org).

F. ABDOMEN

Abdominal organ situs should be determined (51). The fetal stomach should be identified in its normal position on the left side. Bowel should be contained within the abdomen and the umbilical cord should insert into an intact abdominal wall.

Abnormal fluid collections of the bowel (e.g. enteric cysts, obvious bowel dilatation) should be documented.

Aside from the left-sided stomach, a fetal gallbladder may be seen in the right upper quadrant next to the liver although this latter finding is not a minimum requirement of the

basic scan. Any other cystic structures seen in the abdomen should be referred for a more detailed scan.

The fetal umbilical cord insertion (**Figure 5a**) site should be examined for evidence of a ventral wall defect such as omphalocele or gastroschisis. Cord vessels may also be counted using gray-scale imaging as an optional component of the routine anatomic survey.

G. KIDNEYS AND BLADDER

The fetal bladder and both kidneys should be identified (**Figures 5b and 5c**). If either the bladder or renal pelvis appears enlarged, a measurement should be documented. Persistent failure to visualize the bladder should prompt a referral for a more detailed assessment.

H. SPINE:

A satisfactory examination of the fetal spine requires expertise and meticulous scanning, and the results are heavily dependent upon the fetal position (**Figures 5c and 5d**). Complete evaluation of the fetal spine from every projection is not a part of the basic examination although transverse and sagittal views are usually informative. The most frequent of the severe spinal abnormalities, open spina bifida is usually associated with abnormal intracranial anatomy such as a characteristic cerebellar deformity (“banana sign”) and obliterated cisterna magna. Other views of the fetal spine may identify other spinal malformations including vertebral abnormalities and sacral agenesis (19).

I. LIMBS AND EXTREMITIES

The presence or absence of both arms/hands (**Figure 6a**) and both legs/feet (**Figure 6b**) should be documented using a systematic approach (52). Counting fingers or toes is not required as part of the routine mid-trimester scan.

J. GENITALIA

Characterization of external genitalia, to determine fetal gender, is not considered mandatory in the context of a mid-trimester routine scan. Reporting of gender should be considered only with parental consent and in the context of local practices.

K. PLACENTA

During ultrasonography, the placental location (**Figure 6c**), its relationship with the internal cervical os and appearance should be described. Examples of abnormal placental findings include the presence of hemorrhage, multiple cysts with triploidy, and placental masses such as chorioangioma. In most cases of the routine second trimester examination, transabdominal ultrasonography permits clear definition of the relation between the placenta and internal cervical os. If the lower placental edge reaches or overlaps the internal os, a follow-up examination in the third trimester is recommended (53,54).

Women with a history of uterine surgery and low anterior placenta or previa are at risk for placental attachment disorders. In these cases, the placenta should be examined for findings of accreta, the most sensitive of which are the presence of multiple irregular placental lacunae that show arterial or mixed flow (55, 56). Abnormal appearance of the uterine wall-bladder wall interface is quite specific for accreta, but is seen in rather few cases. Loss of the echolucent space between an anterior placenta and uterine wall is neither a sensitive nor a specific marker for placenta accreta. Although placenta accreta may be suspected during a routine mid-trimester scan, a more detailed evaluation is usually required to further examine this possibility.

L. CERVIX, UTERINE MORPHOLOGY AND ADNEXA

Several studies have demonstrated a strong correlation between short cervical length on transvaginal scan and subsequent preterm birth. However, several randomized controlled trials that examined the combination of routine cervical length measurement and subsequent interventions (cerclage, progesterone) failed to conclusively demonstrate cost-effectiveness of

such screening programs (57, 58). Currently, there is insufficient evidence to recommend routine cervical length measurements at mid trimester in an unselected population (59).

Identification of women with short cervical length may have significant benefit for research purposes and further intervention studies, but this is not a justification for routine cervical scanning. Such a universal screening program would not only require significant resources and quality assurance, but also cause potential disadvantages by introducing anxiety and unnecessary intervention.

Uterine fibroids and adnexal masses should be documented if they are likely to interfere with labor (60).

SUPPORTING INFORMATION ON THE INTERNET

The following Supplementary Material may be found in the online version of this article:

Ultrasound Report Form.pdf

REFERENCES:

1. **World Health Organization.** Report on the regional consultation towards the development of a strategy for optimizing fetal growth and development. Cairo, WHO Regional Office for the Eastern Mediterranean, 2005.
2. **Barker DJ, Gluckman PD, Godfrey KM, Harding JE, Owens JA, Robinson JS.** Fetal nutrition and cardiovascular disease in adult life. *Lancet* 1993; 341: 938-41.
3. **Schwarzler P, Senat MV, Holden D, Bernard JP, Masroor T, Ville Y.** Feasibility of the second-trimester fetal ultrasound examination in an unselected population at 18, 20 or 22 weeks of pregnancy: a randomized trial. *Ultrasound Obstet Gynecol* 1999; 14: 92-7.
4. **Saltvedt S, Almstrom H, Kublickas M, Valentin L, Grunewald C.** Detection of malformations in chromosomally normal fetuses by routine ultrasound at 12 or 18 weeks of gestation-a randomised controlled trial in 39,572 pregnancies. *BJOG* 2006; 113: 664-74.
5. **Tegnander E, Williams W, Johansen OJ, Blaas HG, Eik-Nes SH.** Prenatal detection of heart defects in a non-selected population of 30,149 fetuses - detection rates and outcome. *Ultrasound Obstet Gynecol* 2006; 27: 252-65.
6. **Goldberg JD.** Routine screening for fetal anomalies: expectations. *Obstet Gynecol Clin North Am* 2004; 31: 35-50.
7. **Grandjean H, Larroque D, Levi S.** The performance of routine ultrasonographic screening of pregnancies in the Eurofetus Study. *Am J Obstet Gynecol* 1999; 181: 446-54.
8. **World Health Organization.** Training in diagnostic ultrasound: essentials, practice, and standards. Geneva, World Health Organization (WHO Technical Report Series, No. 875), 1998.
9. **Reddy UM, Filly RA, Copel JA.** Prenatal imaging: ultrasonography and magnetic resonance imaging. *Obstet Gynecol* 2008; 112: 145-57.
10. **Ville Y.** 'Ceci n'est pas une echographie': a plea for quality assessment in prenatal ultrasound. *Ultrasound Obstet Gynecol* 2008. 31: 1-5.
11. **Abramowicz JS, Kossoff G, Marsal K, Ter Haar G.** Safety Statement, 2000 (reconfirmed 2003). International Society of Ultrasound in Obstetrics and Gynecology (ISUOG). *Ultrasound Obstet Gynecol* 2003; 21: 100.
12. **Altman DG, Chitty LS.** New charts for ultrasound dating of pregnancy. *Ultrasound Obstet Gynecol* 1997; 10: 174-91.
13. **Degani S.** Fetal biometry: clinical, pathological, and technical considerations. *Obstet Gynecol Surv* 2001; 56: 159-67.

14. **Dudley NJ.** A systematic review of the ultrasound estimation of fetal weight. *Ultrasound Obstet Gynecol*, 2005; 25: 80-9.
15. **Salomon LJ, Bernard JP, Duyme M, Doris B, Mas N, Ville Y.** Feasibility and reproducibility of an image scoring method for quality control of fetal biometry in the second trimester. *Ultrasound Obstet Gynecol* 2006; 27: 34-40.
16. **Salomon LJ, Bernard JP, Duyme M, Buvat I, Ville Y.** The impact of choice of reference charts and equations on the assessment of fetal biometry. *Ultrasound Obstet Gynecol* 2005; 25: 559-65.
17. **Hadlock FP, Harrist RB, Shah YP, King DE, Park SK, Sharman RS.** Estimating fetal age using multiple parameters: a prospective evaluation in a racially mixed population. *Am J Obstet Gynecol* 1987;156:955-7.
18. **Taipale P, Hiilesmaa V.** Predicting delivery date by ultrasound and last menstrual period in early gestation. *Obstet Gynecol* 2001; 97: 189-94.
19. **International Society of Ultrasound in Obstetrics and Gynecology.** Sonographic examination of the fetal central nervous system: guidelines for performing the 'basic examination' and the 'fetal neurosonogram'. *Ultrasound Obstet Gynecol* 2007; 29: 109-16.
20. **Hadlock FP, Deter RL, Carpenter RJ, Park SK.** Estimating fetal age: effect of head shape on BPD. *AJR Am J Roentgenol* 1981; 137: 83-5.
21. **Jago JR, Whittingham TA, Heslop R.** The influence of ultrasound scanner beam width on femur length measurements. *Ultrasound Med Biol* 1994; 20: 699-703.
22. **Lessoway VA, Schulzer M, Wittmann BK.** Sonographic measurement of the fetal femur: factors affecting accuracy. *J Clin Ultrasound* 1990; 18: 471-6.
23. **Hadlock FP, Harrist RB, Sharman RS, Deter RL, Park SK.** Estimation of fetal weight with the use of head, body, and femur measurements - a prospective study. *Am J Obstet Gynecol* 1985; 151: 333-7.
24. **Mongelli M, Ek S, Tambyrajia R.** Screening for fetal growth restriction: a mathematical model of the effect of time interval and ultrasound error. *Obstet Gynecol* 1998; 92: 908-12.
25. **Tunón K, Eik -Nes SH, Grøttum P.** Fetal outcome when the ultrasound estimate of the day of delivery is more than 14 days later than the last menstrual period estimate. *Ultrasound Obstet Gynecol* 1999;14:17-22.
26. **Tunón K, Eik -Nes SH, Grøttum P.** A comparison between ultrasound and a reliable last menstrual period as predictors of the day of delivery in 15,000 examinations. *Ultrasound Obstet Gynecol* 1996;8:178-85.

27. **Johnsen SL, Rasmussen S, Wilsgaard T, Sollien R, Kiserud T.** Longitudinal reference ranges for estimated fetal weight. *Acta Obstet Gynecol Scand* 2006; 85: 286-97.
28. **Salomon LJ, Bernard JP, Ville Y.** Estimation of fetal weight: reference range at 20-36 weeks' gestation and comparison with actual birth-weight reference range. *Ultrasound Obstet Gynecol* 2007; 29: 550-5.
29. **Magann EF, Chauhan SP, Whitworth NS, Isler C, Wiggs C, Morrison JC.** Subjective versus objective evaluation of amniotic fluid volume of pregnancies of less than 24 weeks' gestation: how can we be accurate? *J Ultrasound Med* 2001; 20: 191-5.
30. **Magann EF, Perry, Jr. KG, Chauhan SP, Anfanger PJ, Whitworth NS, Morrison JC.** The accuracy of ultrasound evaluation of amniotic fluid volume in singleton pregnancies: the effect of operator experience and ultrasound interpretative technique. *J Clin Ultrasound* 1997; 25: 249-53.
31. **de Vries JI, Fong BF.** Normal fetal motility: an overview. *Ultrasound Obstet Gynecol* 2006; 27: 701-11.
32. **Bonilla-Musoles F, Machado LE, Osborne NG.** Multiple congenital contractures (congenital multiple arthrogryposis). *J Perinat Med* 2002; 30: 99-104.
33. **Manning FA.** Fetal biophysical profile. *Obstet Gynecol Clin North Am* 1999; 26: 557-77.
34. **Alfirevic Z, Neilson JP.** The current status of Doppler sonography in obstetrics. *Curr Opin Obstet Gynecol* 1996; 8: 114-8.
35. **Neilson JP, Alfirevic Z.** Doppler ultrasound for fetal assessment in high-risk pregnancies. *Cochrane Database Syst Rev* 2000; CD000073.
36. **Alfirevic Z, Stampalija T, Gyte GM.** Fetal and umbilical Doppler ultrasound in high-risk pregnancies. *Cochrane Database Syst Rev* 2010; CD007529.
37. **Heinonen S, Ryyänänen M, Kirkinen P, Saarikoski S.** Perinatal diagnostic evaluation of velamentous umbilical cord insertion: clinical, Doppler, and ultrasonic findings. *Obstet Gynecol* 1996;87:112-7.
38. **Pretorius DH, Chau C, Poeltler DM, Mendoza A, Catanzarite VA, Hollenbach KA.** Placental cord insertion visualization with prenatal ultrasonography. *J Ultrasound Med* 1996;15:585-93.
39. **Gagnon R, Morin L, Bly S, et al.** Guidelines for the management of vasa previa. *Obstet Gynaecol Can* 2009;31:748-60
40. **Aubry MC, Aubry JP, Dommergues M.** Sonographic prenatal diagnosis of central nervous system abnormalities. *Childs Nerv Syst* 2003; 19: 391-402.

41. **Miller C, Losken HW, Towbin R, Bowen A, Mooney MP, Towbin A, Faix RS.** Ultrasound diagnosis of craniosynostosis. *Cleft Palate Craniofac J* 2002; 39: 73-80.
42. **Brown BS.** The prenatal ultrasonographic diagnosis of osteogenesis imperfecta lethalis. *J Can Assoc Radiol* 1984; 35: 63-6.
43. **Rotten D, Levailant JM.** Two- and three- dimensional sonographic assessment of the fetal face. 1. A systematic analysis of the normal face. *Ultrasound Obstet Gynecol* 2004; 23: 224-31.
44. **Dar P, Gross SJ.** Craniofacial and neck anomalies. *Clin Perinatol* 2000; 27: 813-37.
45. **Azouz EM, Teebi AS, Eydoux P, Chen MF, Fassier F.** Bone dysplasias: an introduction. *Can Assoc Radiol J* 1998; 49: 105-9.
46. **Ruano R, Benachi A, Aubry MC, Bernard JP, Hameury F, Nihoul-Fekete C, Dumez Y.** Prenatal sonographic diagnosis of congenital hiatal hernia. *Prenat Diagn* 2004; 24: 26-30.
47. **Blaas HG, Eik-Nes SH.** Sonographic development of the normal foetal thorax and abdomen across gestation. *Prenat Diagn* 2008; 28: 568-80.
48. **International Society of Ultrasound in Obstetrics and Gynecology.** Cardiac screening examination of the fetus: guidelines for performing the 'basic' and 'extended basic' cardiac scan. *Ultrasound Obstet Gynecol* 2006; 27: 107-13.
49. **Comstock CH.** Normal fetal heart axis and position. *Obstet Gynecol* 1987; 70: 255-9.
50. **Yagel S, Arbel R, Anteby EY, Raveh D, Achiron R.** The three vessels and trachea view (3VT) in fetal cardiac scanning. *Ultrasound Obstet Gynecol* 2002; 20: 340-5.
51. **Bronshtein M, Gover A, Zimmer EZ.** Sonographic definition of the fetal situs. *Obstet Gynecol* 2002; 99: 1129-30.
52. **Holder-Espinasse M, Devisme L, Thomas D, Boute O, Vaast P, Fron D, Herbaux B, Puech F, Manouvrier-Hanu S.** Pre- and postnatal diagnosis of limb anomalies: a series of 107 cases. *Am J Med Genet A* 2004; 124A: 417-22.
53. **Bhide A, Thilaganathan B.** Recent advances in the management of placenta previa. *Curr Opin Obstet Gynecol* 2004; 16: 447-51.
54. **Royal College of Obstetricians and Gynaecologists.** Guideline No. 27. Placenta praevia and placenta praevia accreta: diagnosis and management. October, 2005.
55. **Finberg HJ, Williams JW.** Placenta accreta: prospective sonographic diagnosis in patients with placenta previa and prior cesarean section. *J Ultrasound Med* 1992; 11: 333-43.

56. **Comstock CH, Love Jr. JJ, Bronsteen RA, Lee W, Vettraino IM, Huang RR, Lorenz RP.** Sonographic detection of placenta accreta in the second and third trimesters of pregnancy. *Am J Obstet Gynecol* 2004; 190: 1135-40.
57. **Fonseca EB, Celik E, Parra M, Singh M, Nicolaides KH.** Progesterone and the risk of preterm birth among women with a short cervix. *N Engl J Med* 2007; 357: 462-9.
58. **To MS, Alfirevic Z, Heath VC, Cicero S, Cacho AM, Williamson PR, Nicolaides KH.** Cervical cerclage for prevention of preterm delivery in women with short cervix: randomised controlled trial. *Lancet* 2004; 363: 1849-53.
59. **Berghella V, Baxter JK, Hendrix NW.** Cervical assessment by ultrasound for preventing preterm delivery. *Cochrane Database Syst Rev* 2009; CD007235.
60. **Qidwai GI, Caughey AB, Jacoby AF.** Obstetric outcomes in women with sonographically identified uterine leiomyomata. *Obstet Gynecol* 2006; 107: 376-82.

Table 1. Minimal Components for the Mid-Trimester Fetal Anatomic Survey

Head	intact cranium cavum septi pellucidi midline falx thalami cerebral ventricles cerebellum cisterna magna
Face	presence of both orbits median facial profile* upper lip intact mouth present
Neck	absence of masses (e.g. cystic hygroma)
Chest/Heart	normal appearing shape / size of the chest and lungs presence or absence of heart activity four-chamber view of the heart in normal position aortic and pulmonary outflow tracts* no evidence for diaphragmatic hernia
Abdomen	stomach in normal position bowel not dilated kidneys cord insertion site
Skeletal	no spinal defects or masses (transverse and sagittal views) arms and hands present, normal relationships legs and feet present, normal relationships
Placenta	position no masses present accessory lobe
Umbilical Cord	three-vessel cord*
Genitalia	male or female (optional)

* optional component of checklist can be evaluated if technically feasible

FIGURES

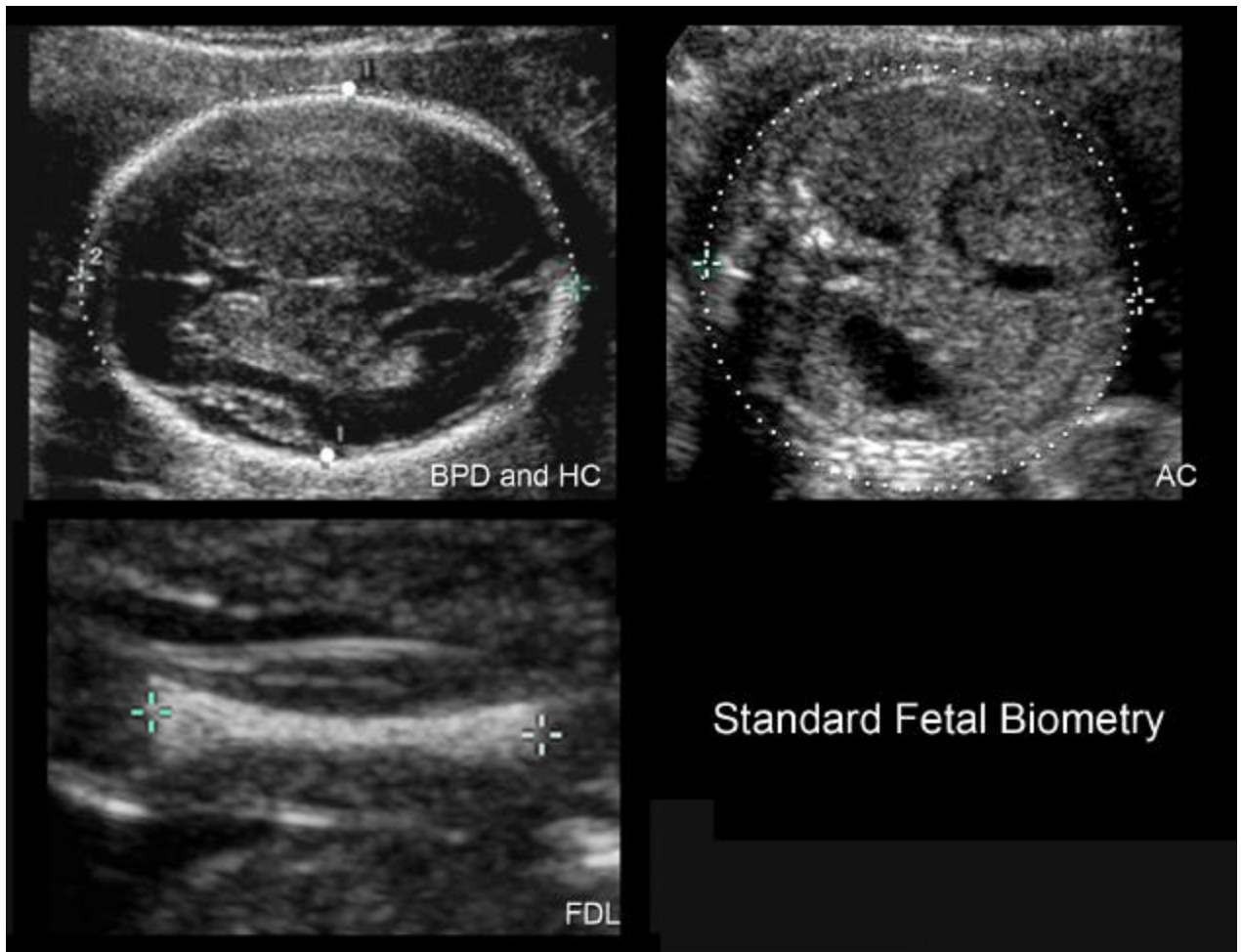


Figure 1. Measurements of the fetal head, abdominal circumference, and femur diaphysis length.

Sonographic measurements are demonstrated for the biparietal diameter (BPD), head circumference (HC), abdominal circumference (AC), and femur diaphysis length (FDL). In this example, callipers are placed on the outer and inner edges of the skull for BPD measurement. Some reference charts have been developed using different calliper placement for the BPD (e.g. outer edge to outer edge of the skull).

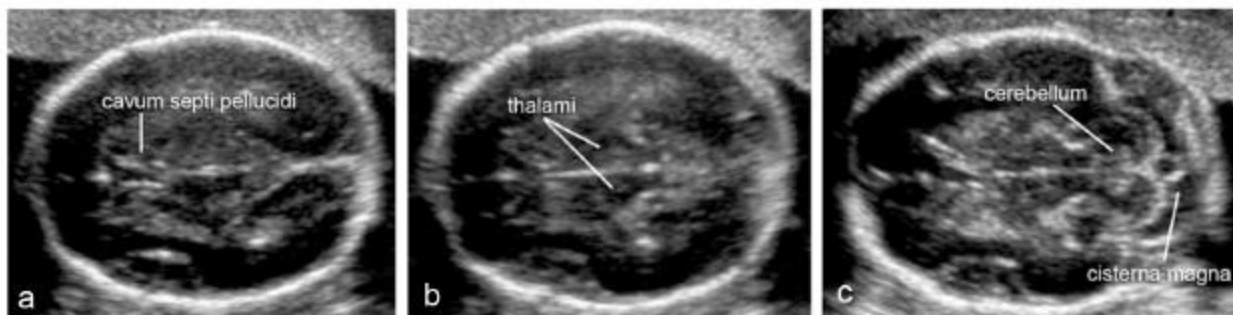


Figure 2. Transverse scanning planes for the fetal brain

Transverse views of the fetal head demonstrate standard transventricular (a), transthalamic, and transcerebellar (c) planes. The first two planes allow assessment of the anatomic integrity of the brain. A third plane permits evaluation of the cerebellum and cisterna magna in the posterior fossa.

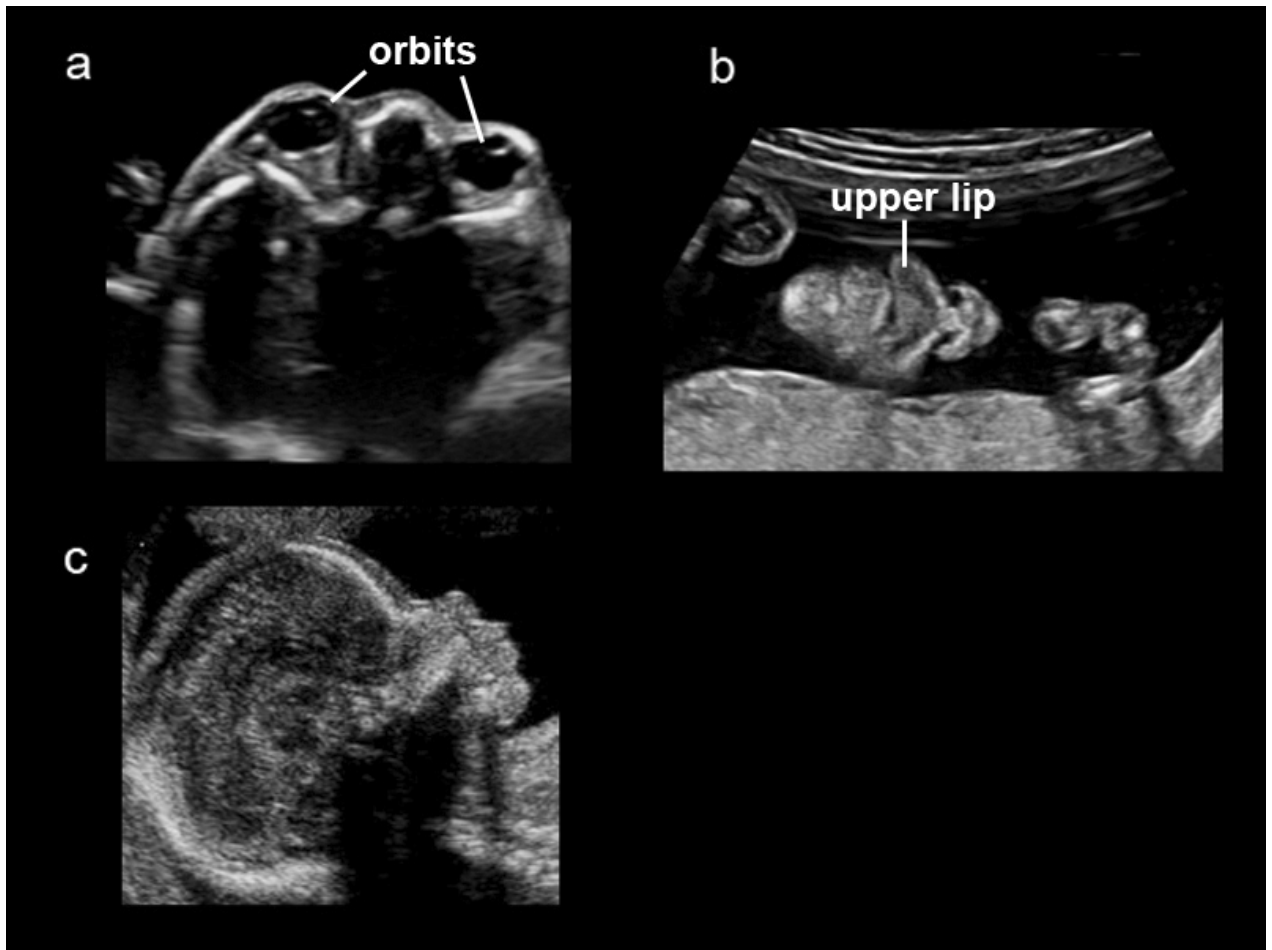


Figure 3. Fetal orbits, nose, mouth, lips, and facial profile

Both fetal orbits should appear symmetrical and intact (**Figure 3a**). The mouth, lips, and nose are typically evaluated with a coronal view (**Figure 3b**). If technically feasible, a median facial profile provides important diagnostic clues for cleft lip, frontal bossing, micrognathia, and nasal bone anomalies (**Figure 3c**).

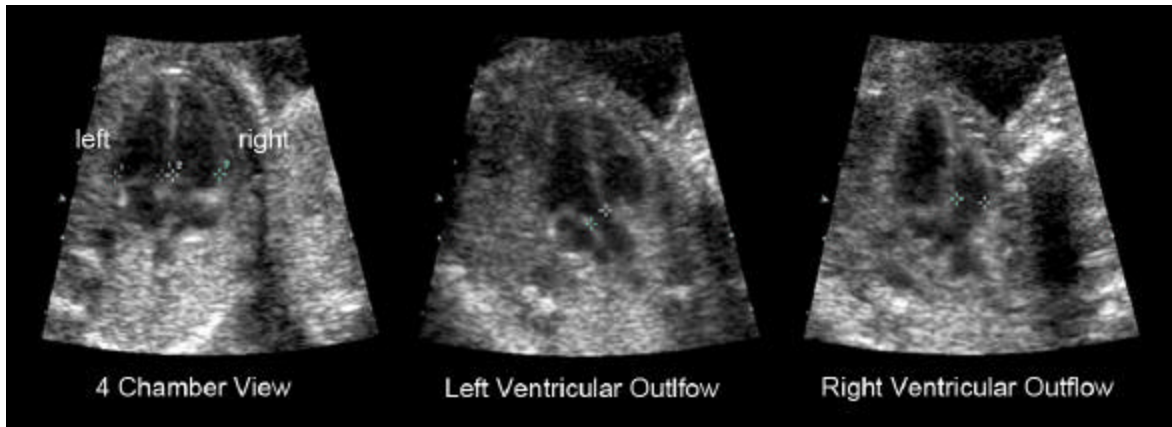


Figure 4. ‘Basic’ and ‘extended basic’ views of the fetal heart.

The ‘basic’ cardiac scan is obtained from a 4-chamber view when both ventricles are seen during end diastole (*callipers, far left panel*). An ‘extended basic’ scan of the great arteries demonstrate the left and right ventricular outflow tracts. Separate arterial outflow tracts (*callipers, middle and far right panel*), approximately equal in size, exit their respective ventricles by crossing over each other in normal fetuses.

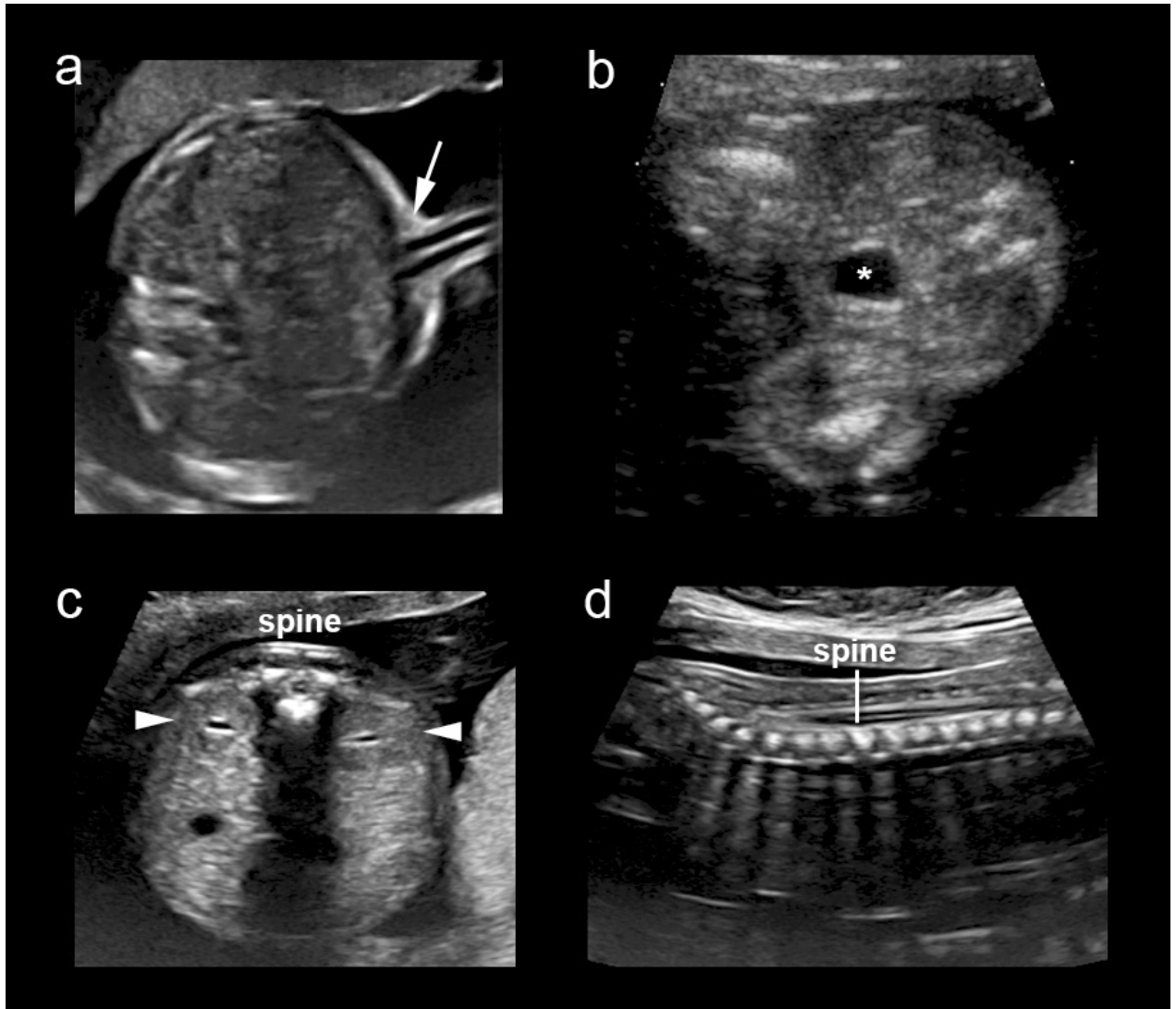


Figure 5.

Fetal cord insertion site, bladder with umbilical arteries, kidneys, and spine.

The umbilical cord insertion site into the fetal abdomen (*arrow*) provides information about the presence of ventral wall defects such as omphalocele or gastroschisis (**Figure 5a**). The fetal bladder (*) and both kidneys (*arrowheads*) should be identified (**Figures 5b and 5c**). Axial and longitudinal views of the spine provide effective screening for spina bifida, especially when these scanning planes are abnormal in the presence of frontal skull deformation and an obliterated cisterna magna. (**Figure 5c and 5d**).

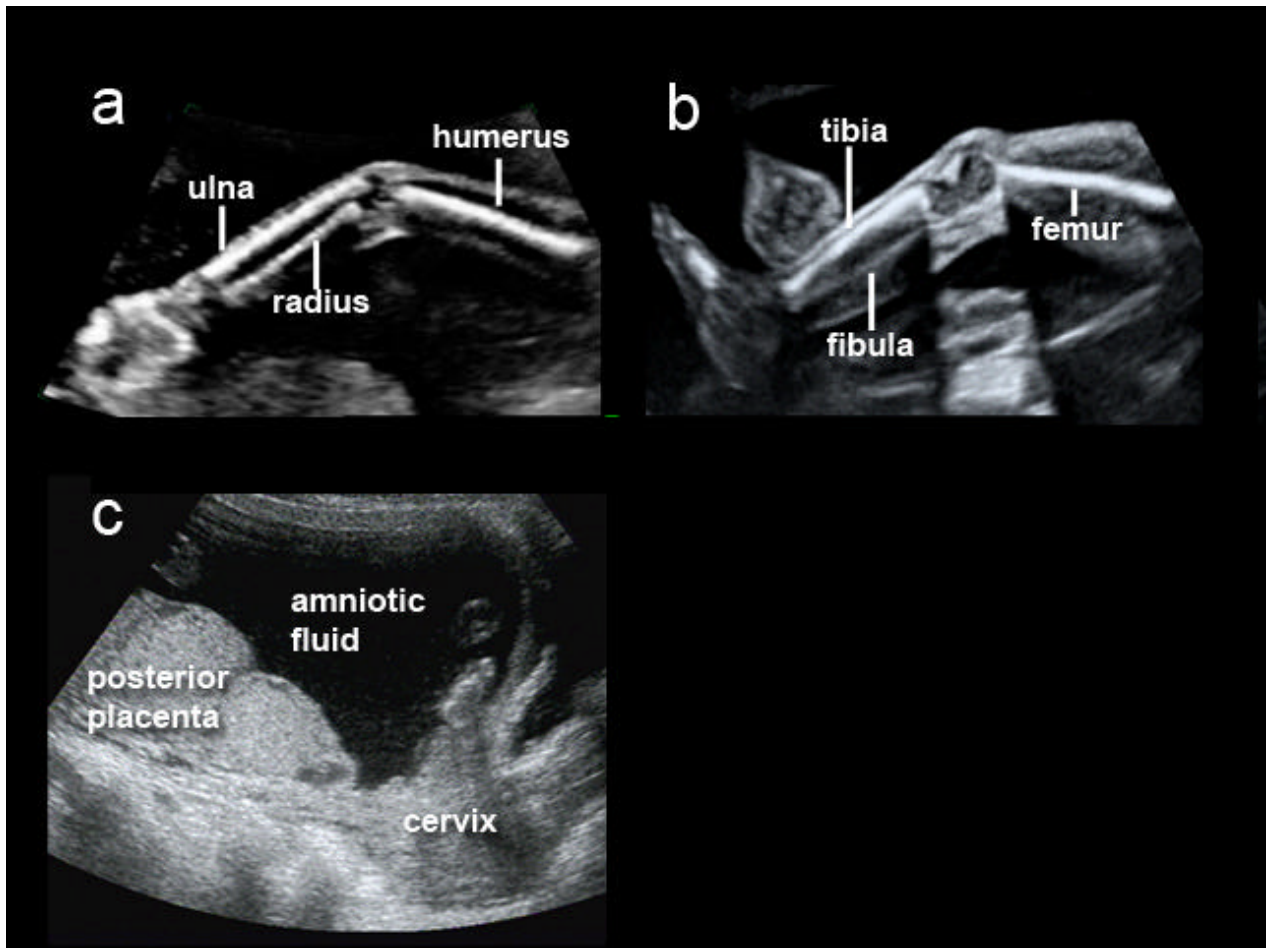


Figure 6.

Fetal upper extremity, lower extremity, and placenta.

The presence or absence of the upper and lower limbs should be routinely documented unless they are poorly visualized due to technical factors (**Figures 6a and 6b**). Placental position should be determined in relation to the maternal cervix (**Figure 6c**).

ACKNOWLEDGEMENTS

These Guidelines were developed by the Prenatal Ultrasound Screening Task Force under the auspices of the ISUOG Clinical Standards Committee; Chair, Dr. Wesley Lee.

Appreciation is particularly extended to specialty consultants who contributed to this project:

Task Force Chair: Laurent J Salomon, MD, PhD

Hôpital Necker Enfants Malades. AP-HP, Université Paris Descartes
Paris, France

Zarko Alfirevic, MD

Division of Perinatal and Reproductive Medicine, University of Liverpool
Liverpool Women's Hospital, United Kingdom

Vincenzo Berghella, MD

Department of Obstetrics and Gynecology, Thomas Jefferson University
Philadelphia, USA

Caterina Bilardo, MD

Department of Obstetrics and Gynecology, Academic Medical Centre
Amsterdam, Netherlands

Edgar Hernandez-Andrade, MD

Department of Maternal Fetal Medicine, National Institute of Perinatal Medicine
Mexico City, Mexico

Synnove Lian Johnsen, MD

Haukeland University Hospital,
Bergen, Norway

Karim Kalache, MD

Department of Obstetrics, Charité University Hospital-Campus Mitte
Berlin, Germany

Wesley Lee, MD

Department of Obstetrics and Gynecology. William Beaumont Hospital
Royal Oak, Michigan, USA

Kwok Yin Leung, MD

Department of Obstetrics and Gynecology. Queen Mary Hospital, The University of Hong Kong, Hong Kong, China

Gustavo Malinger, MD

Fetal Neurology Clinic, Department of Obstetrics and Gynecology, Wolfson Medical Center
Tel-Aviv University, Israel

Hernan Munoz, MD , FACOG

Department Obstetrics and Gynecology. Universidad de Chile
Clinica Las Condes
Santiago Chile

Federico Prefumo, MD, PhD

Department of Obstetrics and Gynecology, University of Brescia
Brescia, Italy

Ants Toi, MD

Mount Sinai Hospital
Department of Medical Imaging, University of Toronto
Toronto, Canada

Special appreciation to Jacques Abramowicz (USA), MD, PhD for his contribution to the Safety section and to Jean-Philippe Bault (France), MD for providing some of the images.

Copies of this document will be available at:

<http://www.isuog.org>

ISUOG Secretariat

Unit 4, Blythe Mews


Blythe Road

London W14 0HW, UK


e-mail: info@isuog.org

Mid-Trimester Fetal Ultrasound Scan Report Form

Patient: _____ **ID number:** _____



Date Of Birth (DD/MM/YYYY): _____
Referring physician: _____



Date of exam (DD/MM/YYYY): _____
Sonographer / Supervisor: _____

Indication for scan and relevant clinical information:

Gestational Age (W + D):
Based on: *LMP* / *previous US* / *Other* :

Technical conditions: *Good* / *Limited by:*
Singleton / **Multiple (use 1 sheet/fetus)**
=> **Chorionicity:**

PLACENTA: Position:
Relation to cervical os: clear covering ____ mm from os
Appearance Normal Abnormal*

AMNIOTIC FLUID: Normal Abnormal*

FETAL MOVEMENT: Normal Abnormal*

MEASUREMENTS	mm	Percentile (References)
Biparietal Diameter		
Head Circumference		
Abdominal Circumference		
Femur Diaphysis Length		
Other:		
Other:		
Other:		

***Abnormal findings (please detail):**

CONCLUSION:

Normal and complete examination.
 Normal but incomplete examination.
 Abnormal examination*
 Plans: No further ultrasound scans required
 Follow up planned in weeks.
 Referred to
 Other:

SONOGRAPHIC APPEARANCE OF FETAL ANATOMY: (N=Normal; Ab=Abnormal*; NV=Not visualized) Grey=optional	N	Ab*	NV
Head			
Shape			
Cavum septi pellucidi			
Midline falx			
Thalami			
Lateral ventricle			
Cerebellum			
Cisterna magna			
Face			
Upper lip			
Orbits			
Profile			
Neck			
Thorax			
Shape			
No masses			
Heart			
Heart activity			
Size			
Cardiac axis			
4 chamber view			
Left Ventricular Outflow			
Right Ventricular Outflow			
Abdomen			
Stomach			
Bowel			
Kidneys			
Urinary bladder			
Abdominal cord insert.			
Cord vessels (optional)			
Spine			
Limbs			
Right arm (incl. hand)			
Right leg (incl. foot)			
Left arm (incl. hand)			
Left leg (incl. foot)			
Gender (optional): <input type="checkbox"/> M <input type="checkbox"/> F			
Other :			

	Produced	Printed	Stored
No. of images			